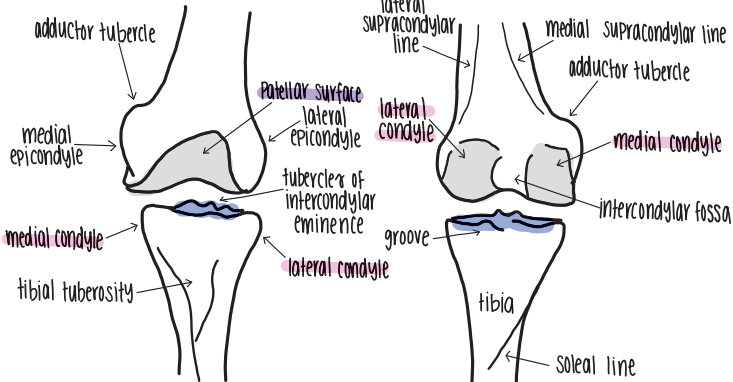
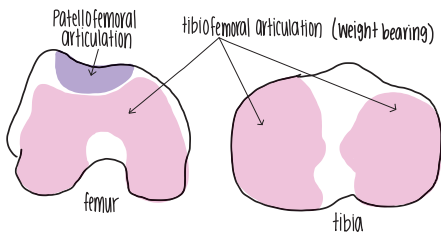


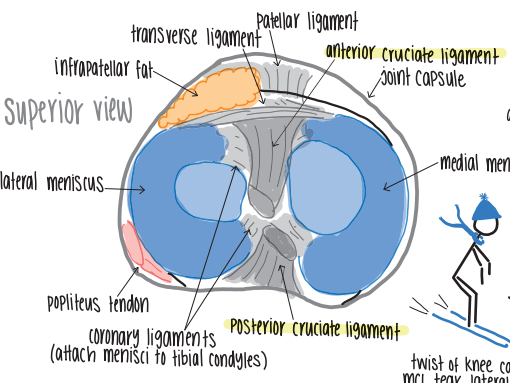
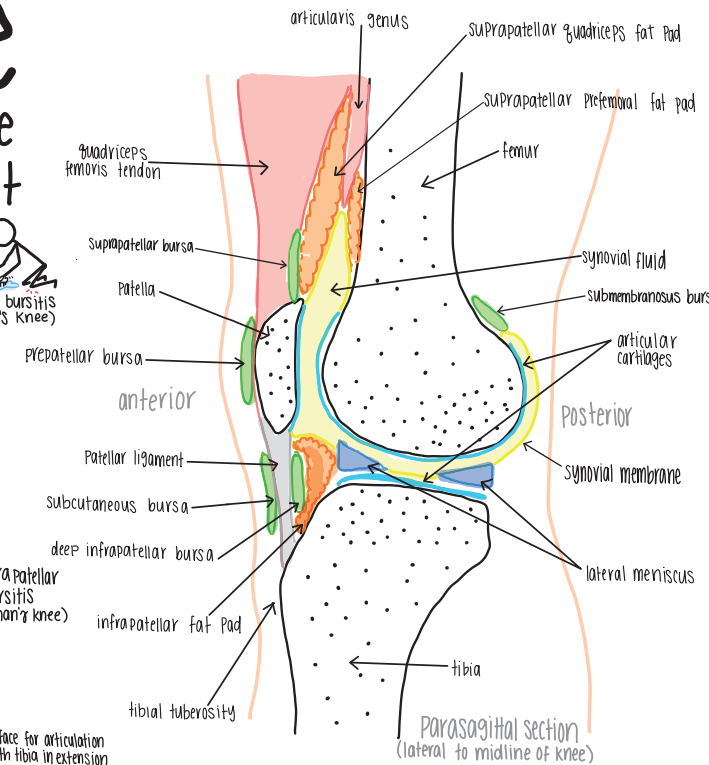
Knee

a hinge type synovial joint

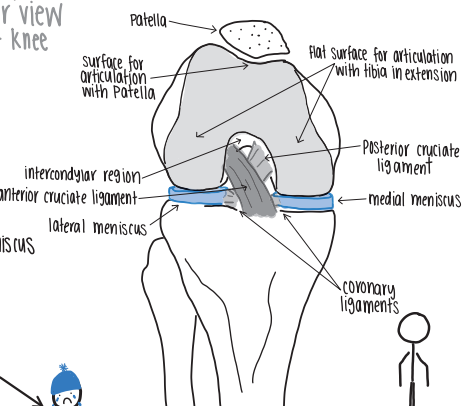


anterior view of left knee (without patella)

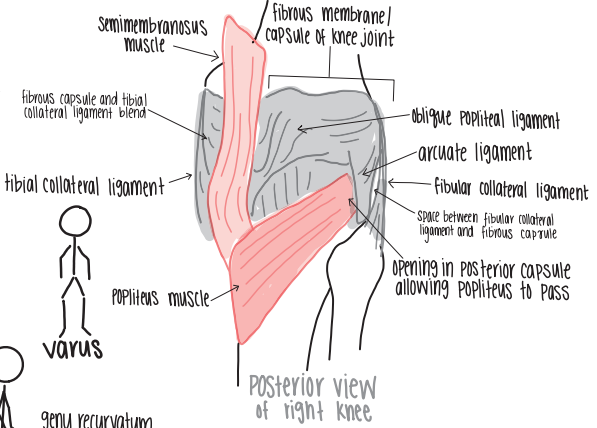
posterior view of left knee



superior view



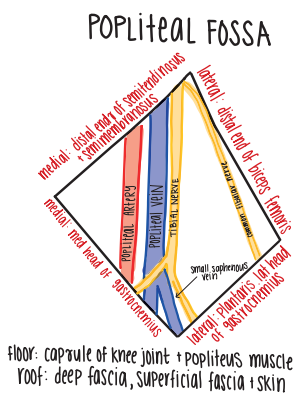
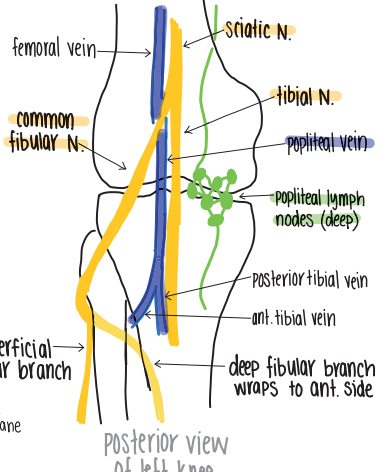
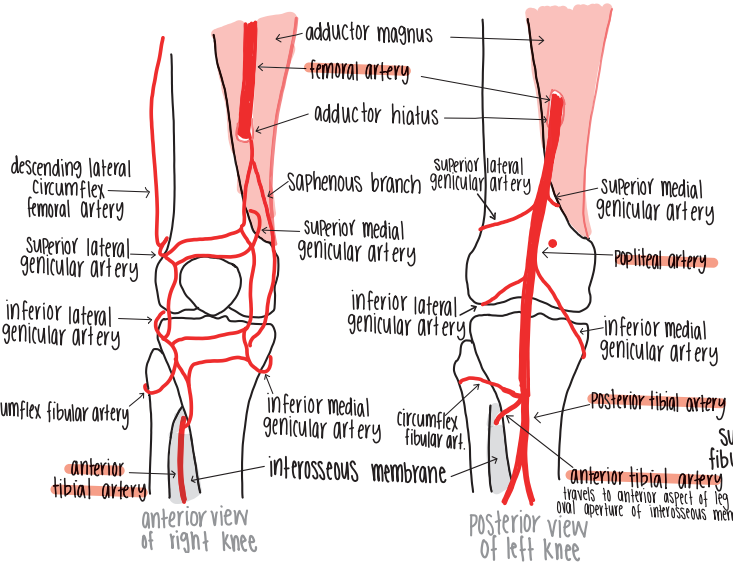
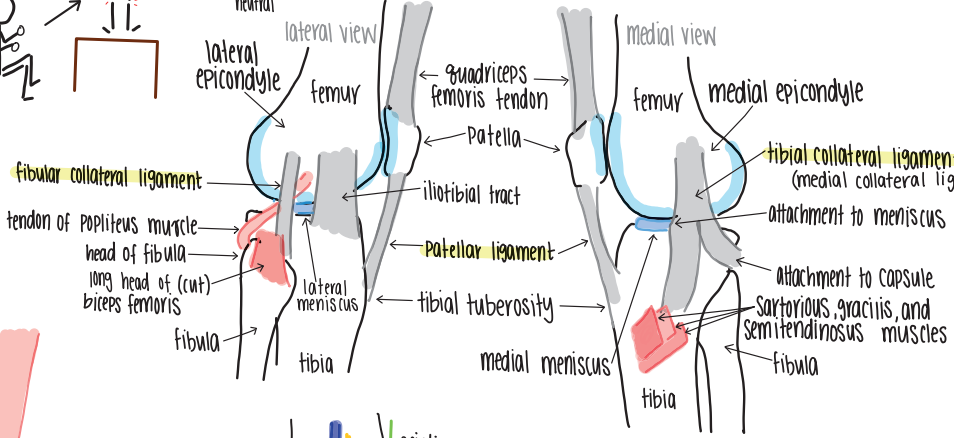
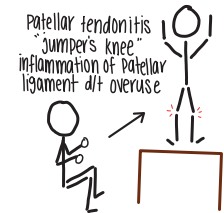
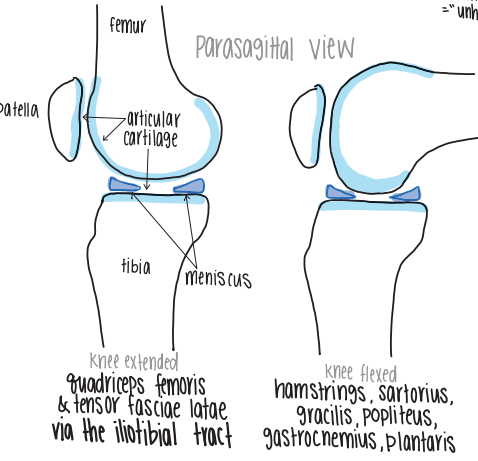
anterior view of right knee flexed



posterior view of right knee



genu recurvatum hyperextension of knee d/t laxity in ligaments



References:

Netter, F. H. (2018). *Atlas of Human Anatomy*, 7th Ed. Philadelphia, PA: Saunders/Elsevier. Print.

Drake, R. L., Vogl, A. W., Mitchell, A. (2019). *Gray's Anatomy for Students*, 4th Ed. Philadelphia, PA: Saunders/Elsevier. Print.

Abrahams, P.H., Spratt, J. D., Loukas, M., van Schoor, A. (2013) *McMinn and Abrahams' Clinical Atlas of Human Anatomy*, 7th Ed. Saunders/Elsevier. Ebook.

Coakley, B. *Anatomy Drawings - Upper Limb*. Digitised copy made available to UCD Medical Students.